3.9 Biological Effects of Shockwaves

3.9.1 Historical Aspects

The clinical application of shockwaves for contact-free kidney stone disintegration was based on the following experimental results (Table 3.1):

- The growth behavior of human lymphocyte cultures remained unaffected.
- The in vitro hemolysis of human blood could not be demonstrated in the peripheral blood under in vivo conditions.
- Shock wave treatment of eviscerated parenchymal organs and muscle tissues of rats (liver, kidney, spleen) did not produce any irreversible lesions.
- A fracture discovered in cadaver bones could not be demonstrated in the case of vital bony tissue.
- Shock wave treatment of eviscerated, air-

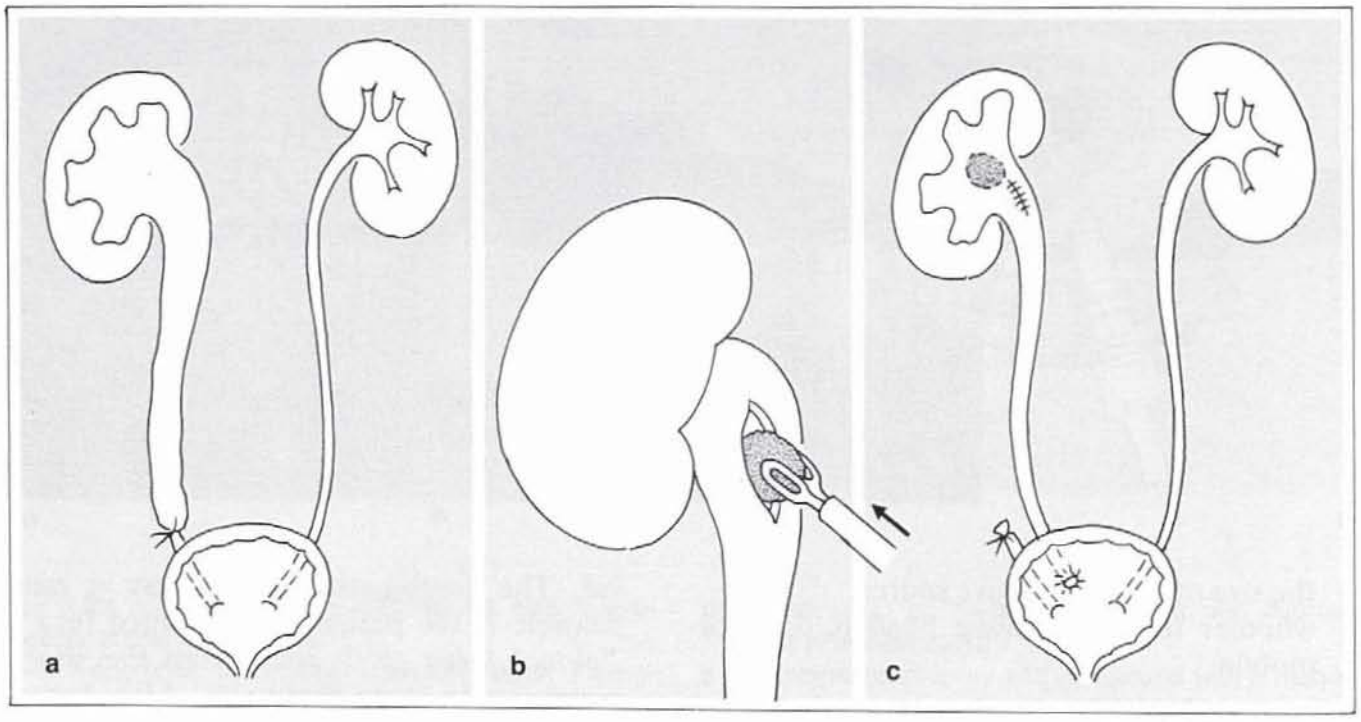

Fig. 3.24 **Canine kidney stone model for experimental studies of ESWL**

a Prevesical ligation of right ureter inducing dilatation of the upper urinary tract

b Surgical implantation of human kidney stones in the dilated renal pelvis

c Reimplantation of the right ureter (Politano-Leadbetter technique)

filled rat intestines lead to petechial hemorrhage. There were no comparable changes with intestines void of air.
- Shock wave application to lung tissue resulted in alveolar ruptures as a result of the different impedance of the alveolar air and the parenchyma.

Using the animal model (dogs) with implanted human kidney stones, disintegration could be achieved by ESWL. Shock wave treatment effected spontaneous passage of stone debris without damage to the experimental animals (Fig. 3.**24**).

As clinical experience progressed very quickly, demonstrating only minimal side effects and a very low complication rate, there was only minor interest in the biological effects of shock waves on experimental models. However, the introduction of second generation lithotriptors and reports on the higher incidence of hypertension subsequent to ESWL has lead to increasing interest and a number of experiments in this field.

Generally, the bioeffects of shock waves are described in the following ways:

- as side effects of clinical ESWL;
- as injury to organs or tissues that have been exposed to shock waves;
- as damage of cells in culture that have been treated with shock waves.

The extent of the lesion depends on the amount of applied shock wave energy, which may be classified physically by the peak positive and negative pressure, focal size, the number of impulses, and the degree of shock wave attenuation by the surrounding tissue or material.

3.9.2 Clinical Side Effects

Today, the side effects of ESWL are equivocally classified as follows:

- pain
- skin petechiae or ecchimosis
- hematuria
- renal injury

Pain. With the Dornier HM3 or a comparable system, general or epidural anesthesia was required because the *pain during treatment* was intolerable. However, modification of the generator and the ellipsoid, as well as the introduction of other energy sources with an increased aperture (i.e., piezoceramic elements), now enables ESWL to be performed without anesthesia (Figs. 3.**15**; 3.**25**).

Principally, two types of pain are experienced during shock wave lithotripsy: (1) a superficial pain at the surface of the skin, and (2) a visceral pain in the kidney. The main factors for the induction of pain are (Fig. 3.**15**).

- the peak pressure of the shock wave in the focus;
- the size of the focal zone;
- the area of shock wave penetration on the skin corresponding to the focusing system.

The most important factor of pain sensation seems to be the distribution of shock wave pressure at the skin. This corresponds to the aperture of the focusing system. The aperture should exceed 20 cm to allow pain-free application.

The size of the focal zone and the peak pressure of the shock wave seems to be responsible for visceral pain. At the start of treatment, the visceral pain is more or less tolerable when working with the new modified lithotriptors. However, after the application of more than one thousand shocks, it may become intolerable; this reflects dose-dependent renal trauma by ESWL.

There are further factors of pain that have not yet been fully investigated (i.e., duration of the shock wave impulse and cavitation at the surface of the skin). The latter may be responsible for local skin *petechiae or ecchimosis* on shock wave entry; this occurs in about 10%–20% of the patients.

Renal trauma. In contrast to early experimental results, some renal injury resulting from ESWL therapy has been frequently documented using different imaging techniques and laboratory studies (Tables 3.**4**, 3.**5**).

Renal trauma induced by ESWL varies from mild contusion to large perirenal hematoma. Minor renal traumatization reflects in *gross hematuria*, which is apparent in most of the cases. Whereas computed tomography (CT) scans and ultrasound usually fail to detect such lesions, magnetic resonance imaging (MRI) shows minor morphological changes (i.e., loss of corticomedullary demarcation and perirenal fluid; Table 3.**5**).

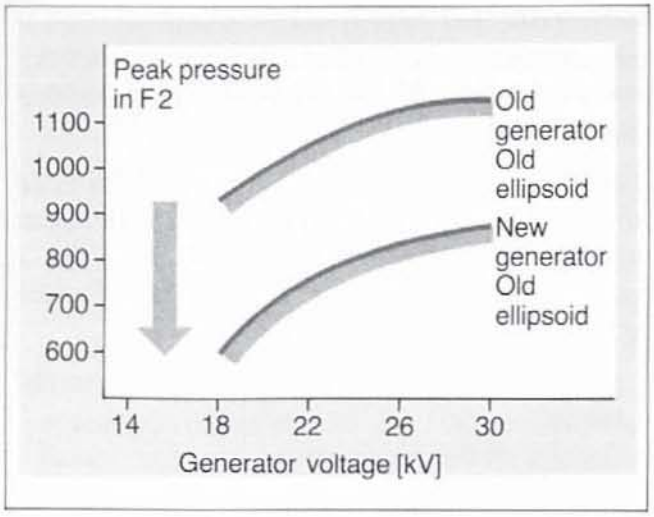

a

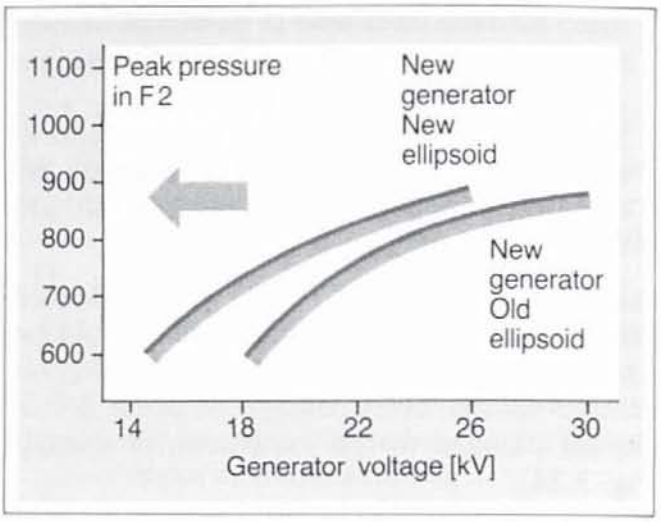

b

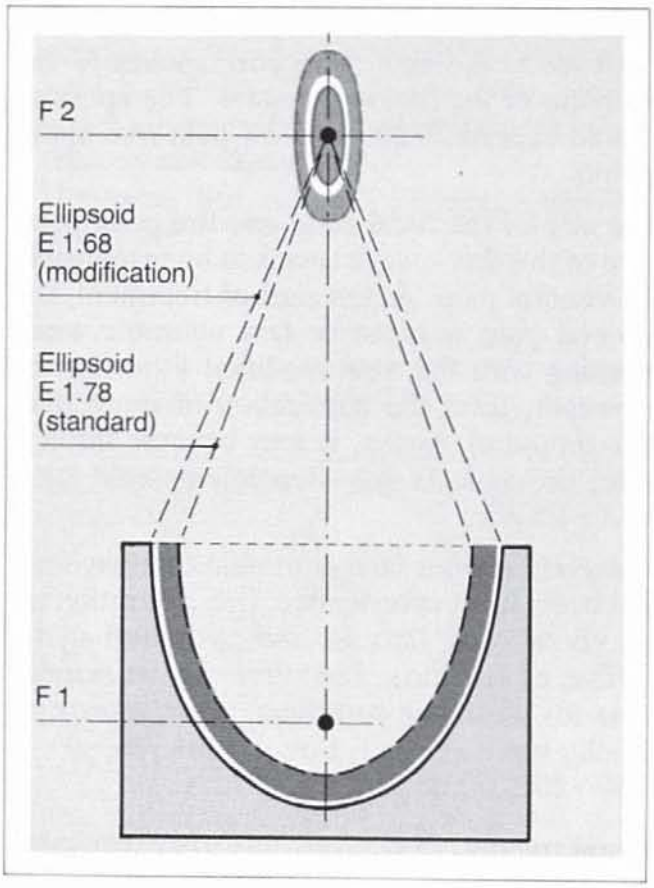

c

Fig. 3.**25** **Technical modifications of the standard Dornier HM3 providing low pressure ESWL under intravenous analgesia (= HM3+).** All measurements were made with a PCB transducer

a Diagram of peak pressure in F2 using the old generator (80 nF), and the new generator (40 nF) with the old ellipsoid

b Diagram of peak pressure in F2 using the old ellipsoid (15 cm), and the new ellipsoid (17 cm) with the new generator (40 nF)

c Schematic drawing of the two ellipsoids. Increase of the aperture size results in decrease of the size of the focal zone

Due to the low number of cases, no definite correlation could be found to the number of shock waves or generator voltage. However, it seems that patients suffering from hypertension had a greater tendency towards hematomas. The majority of these hematomas were managed conservatively and disappeared within two to three months. A perirenal hematoma, in contrast, occurs in less than 0.5% (Fig. 3.**26**).

Moreover, temporary increase of cytoplasmic enzymes (i.e., NAG, γGT in blood and urine) or proteins (β-micro-globulin) in urine (Fig. 3.**27**) demonstrate such injury (Table 3.**4**).

Table 3.4 **Pathophysiological effects of shock waves on the human kidney**

Functional Test	Result	Reference	
Renal plasma flow	No or minor difference between treated and untreated kidney	Thomas et al	1988
Renal plasma flow	5% reduced flow in treated kidneys in 33% of cases	Kaude et al	1985
Excreted enzymes and antigens	Alterations of distal tubular epithelium	Schulze et al	1988
Proximal tubular enzymes	Perirenal soft-tissue trauma, possible glomerular dysfunction	Krongrad et al	1988
Lactate dehydrogenase (LDH) N-acetylglucosaminidase (NAG)	Increase in blood and urine, increase in urine	Marcellan et al	1986
Lactate dehydrogenase (LDH) N-acetylglucosaminidase (NAG) Glutamic pyruvic transaminase (GPT)	Transient increase in blood and urine	Kishimoto et al	1986
N-acetylglucosaminidase (NAG) activity	Temporary renal dysfunction	Das et al	1988
Fibrinolytic system	Increase of coagulative fibrinogen	Di Cello et al	1988
Urinary excretion of lysozyme, -glutamyl-transferase	Transient increase; after 6 months the tubular functions had been restored to normal	Jaeger et al	1988
Urinary proteins	Temporary increase of albumin, IgG, beta-2-microglobulin, Tamm-Horsfall protein; alteration of glomerular permeability	Steinmann et al	1988

Table 3.5 **Side effects of shock waves (SW) after clinical ESWL**

Organ	Result	References	
Kidney	MRI: dose-dependent subcapsular fluid collections and hemorrhages, no serious renal pathologic condition	Baumgartner et al Jordan et al	1987 1982
	CT: identical results	Grote et al Rubin et al	1986 1987
	MRI: renal contusion, subcapsular hematoma, hemorrhage into renal tissue	Arduan et al	1988
	Hemoglobinuria, decrease in renal function, local contusion, pain, focal fibrosis	Drach et al	1988
Skin	renal contusions	Kaude et al	1985
	Petechial bleeding at areas where SW enter the body	Eisenberger and Rassweiler Wilbert	1986 1987
Heart	Incidence of ventricular arrhythmias	Chaussy Janssens et al	1986 1988
Blood pressure	Incidence of hypertension (8%)	Steele et al Lingeman et al	1988 1987
	No significant incidence of hypertension (3%)	Liedl et al Zwergel et al	1989 1989
Intestine	Gastric, duodenal, and colonic erosions	Karawi et al Cass et al	1987 1988

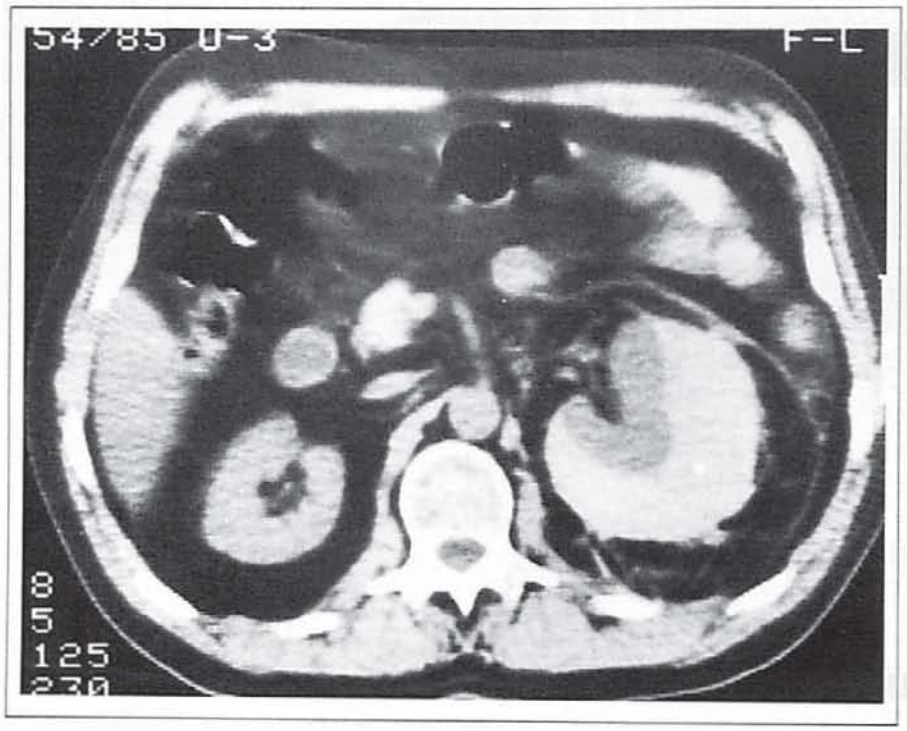

Fig. 3.26 **Large perirenal hematoma after ESWL showed in CT scan.** Conservative management

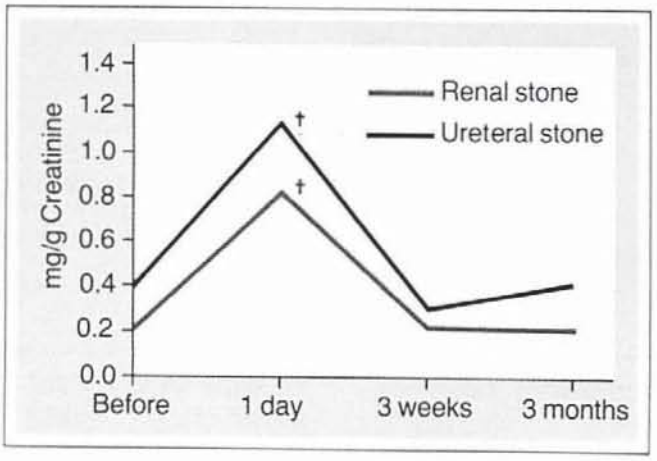

Fig. 3.27 **Urinary beta-2-microglobulin changes following ESWL of renal and ureteral calculi** (from Yokogama et al., 1988)

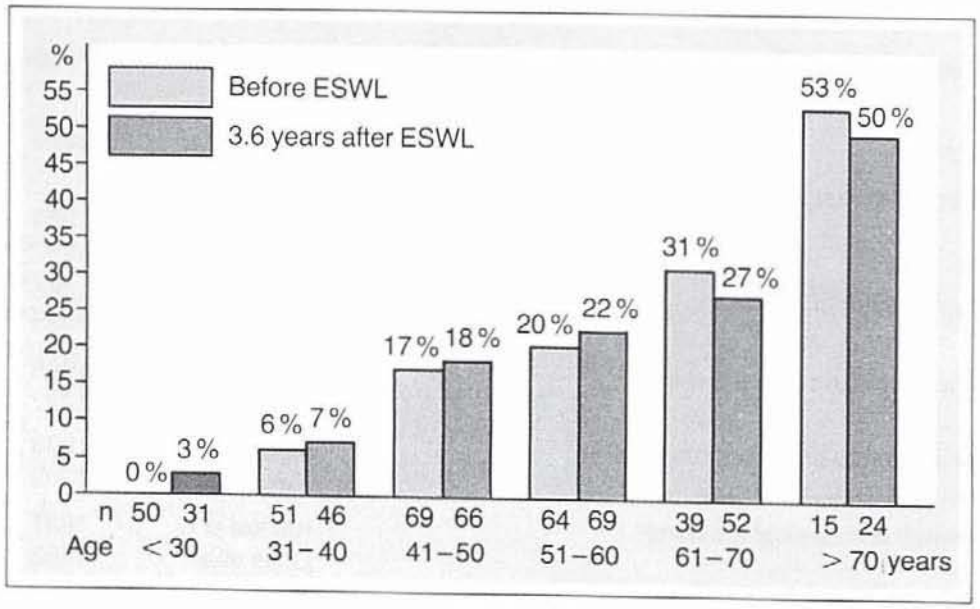

Fig. 3.28 **Age-dependent prevalence of arterial hypertension prior to and 3.6 years after ESWL.** No significant difference (from Liedl et al., 1989)

Chronic changes subsequent to ESWL could not be demonstrated up to present. The early discovery of a higher incidence of arterial hypertension following ESWL could not be substantiated in further studies (Fig. 3.**28**).

Apart from these observations, *extrarenal injury* has very rarely been observed (i.e., gastric, colonic, or duodenal bleeding due to ESWL-induced erosions or minor pulmonary hemorrhage) (Table 3.**5**).

3.9.3 Experimental Animal Studies

Independent of the animal model, the extent of the renal injury by shock waves strictly depends on the energy applied (Table 3.**6**). Low pressure (or generator voltage) leads to only microscopically detectable lesions (i.e., tubular dilatation, rupture of glomerula), whereas higher peak pressures induce intraparenchymal hematomas (Fig. 3.**29**). The size of the hematoma depends on the focal area and the level of generator voltage. Exceedingly high levels (above 1,000 bar) may even lead to perirenal bleeding. The predominant area of the lesion seems to be the corticomedullary junction, owing to rupture of the arcuated veins. However, on high energy levels interlobular arteries may rupture, too, resulting in a perirenal hematoma. Once a hematoma develops, the increase of impulses does not result in greater injury. On the other hand, staged application of shock waves (interval of two days) is less traumatic than the full dose of shocks in a single session (Table 3.**7**).

The long-term observations show healing of the renal lesions by cicatrization; this results in small interstitial or even segmental fibrosis (Fig. 3.**30**), depending on the shock wave energy applied (Table 3.**7**).

Table 3.**8** summarizes the findings when other tissue was exposed to shock waves. No damage was observed in the ureter, the adrenals, and the ovary; however the liver, the bone, the intestines, and the lungs may be damaged by shock waves (Fig. 3.**29b**). Moreover, alteration of the microcirculation has been found after shock wave application.

3.9.4 Cell Culture Experiments and Tumor Models

There is an increasing number of experiments investigating the effect of shock waves on normal and malignant cells (Table 3.**9**). However, some of these findings seem to be contradictory.

- Preliminary studies showed damage of erythrocytes but no significant hemolysis in vivo. Moreover, no influence on the proliferation of human lymphocytes was detected.

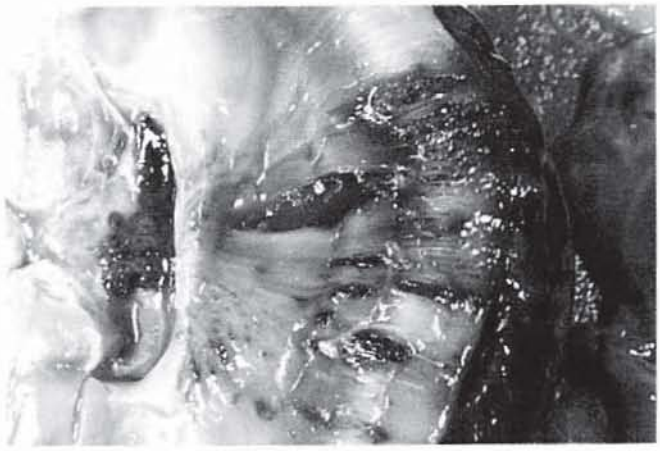

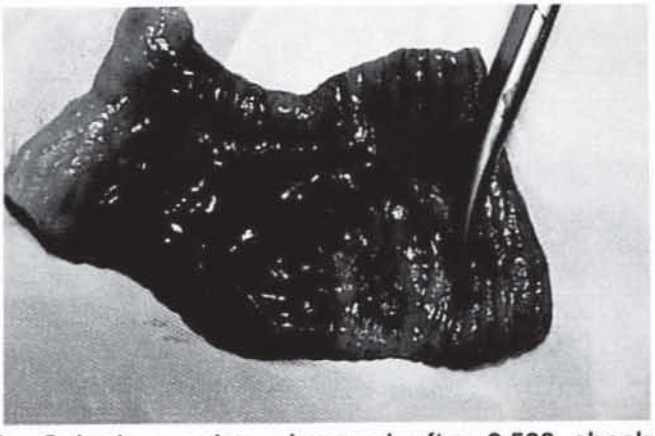

Fig. 3.29 **Acute side-effects in animal studies.**
a **Focal intrarenal hematoma (∅ 1.5 cm) at the corticomedullary junction of a canine kidney** after 2,500 shock waves at 15 kV (~ 550 bar) using a laboratory lithotriptor with electromagnetic shock wave generator (Storz Modulith)
b **Colonic erosion observed after 2,500 shock waves exposed to the right canine kidney** with 18 kV (900 bar) using a laboratory lithotriptor (Storz Modulith)

Table 3.6 **Morphological findings after exposure of canine kidney to different shock wave energy using a new electromagnetic source** (Storz Modulith).

a) Acute changes after 1500 SW and 2500 SW

kV	N	Macroscopy	Histology	Grade of lesions
11–13	7	No lesion or parenchymal petechiae	Minimal tubular necrosis	I
14–16	14	Parenchymal hemorrhage	Rupture of venolae and arteriolae	II
17–20	6	Perirenal hematoma	Rupture of Interlobular arteries	III

b) Acute changes at high energy level (20 kV). The impact of shock wave number

SW; number	N	Macroscopy	Grade of lesion
25– 60	3	Petechial bleeding	I
300– 600	4	Parenchymal hemorrhage	II
900–2500	4	Perirenal hematoma	III

c) Long-term findings 10 weeks after 1500 and 2500 SW

kV	N	Macroscopy	Histology
15	3	No residuals detectable	Hemosiderin residues in the medulla, tubular regeneration
16–17	3	Small cord-like scars at the cortex	Hemosiderin residues and wedge-shaped corticomedullar scar formation
20	3	Residues of parenchymal hematoma perirenal fibrosis	Demarkation of the hematoma, wedge-shaped scar formation

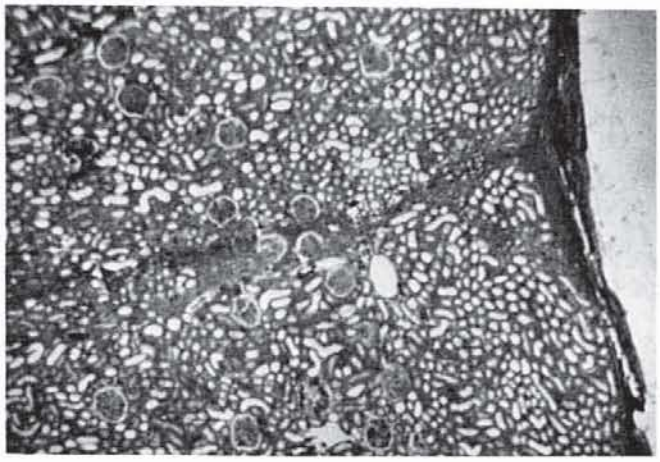

Fig. 3.30 **Long-term changes in the canine kidney.** Segmental fibrosis as a result of healing 10 weeks after a perirenal hematoma due to 2500 shock waves at high-energy level (18 kV) using the Modulith laboratory lithotriptor

Table 3.7 **Shock wave-induced renal trauma in experimental studies**

Lithotriptor	Animal Model (species)	Energy Setting	No. of Shocks	Short-Term Effect	Long-Term Effect (4–6 weeks)	Author
Dornier HM1	Dog	12–15 kV	500	No damage	No visible damage	Chaussy et al 1977
Dornier HM2	Dog	20 kV	500	Intrarenal hematoma (Ø 5 mm)	–	Delius et al 1987
			1,500	Multifocal hematoma (Ø 5 mm)		
			3,000	Multifocal hematoma (Ø 6–18 mm), venous thrombosis		
			3,000 (burst)	Intrarenal (Ø 15 mm) and perirenal hematoma		
Dornier HM3	Dog	18–24 kV	1,600	Intrarenal hematoma (Ø 5 mm)	Small fibrosis	Newman et al 1987
			4,500 6,000	Intrarenal hematoma (Ø 15 mm) and perirenal hematoma	Interstitia fibrosis	
	Dog	–?–	1,500	Intrarenal bleeding and subcapsular hematoma; glomerular rupture, rupture of peritubular venoles	Interstitial fibrosis	Jäger et al 1989
	Pig	15–30 kV	750–12,000	Dose-dependent damage: intrarenal (Ø 10 mm) and perirenal hematoma.	Segmental fibrosis	Muschter et al 1989
				No difference between 6,000 and 12,000 shock waves	Fibrosis of capsule	
	Rat	15 kV	500	Subcapsular and intrarenal bleeding	Interstitial fibrosis	Recker et al 1989
			2,000 5,000	Diffuse hemorrhage and subcapsular bleeding	Segmental fibrosis (severe scarring)	
	Rabbit	14 kV	2,000 + 2,000	Tubular dilatation (2 weeks)	–	Fuchs et al 1989
			4,000	Renal infarction, subcapsular hematoma (2 weeks)	Focal and segmental fibrosis	
	Rabbit	21 kV	500	Intrarenal hematoma (Ø 30 mm)	Segmental fibrosis	Morris et al 1989
Wolf Piezolith 2300	Dog	IV	1,000	Subcapsular hematoma (10 mm)	No visible damage	Kopper et al 1986
		IV	2,000 4,000	Subcapsular hematoma Rupture of arcuate veins, lesion of intima of arterials, necroses of papillae		Neisius et al 1989

Table 3.7 **Shock wave-induced renal trauma in experimental studies** (continued)

Lithotriptor	Animal model (species)	Energy setting	No. of Shocks	Short-Term Effect	Long-Term Effect (4–6 weeks)	Author
	Rabbit	IV	1,000	Subcapsular hematoma (10 mm)	No visible damage	Morris et al 1989
Edap LT01	Dog	100%	6,000 12,000 24,000	Intrarenal hematoma (8–10 mm)	Interstitial fibrosis	Thibault et al 1987
	Rabbit	100%	6,000	No damage	No visible damage	Ryan et al 1989
			24,000	Intrarenal and perirenal bleeding	No visible damage	
Siemens Lithostar	Dog	16–19 kV	500–2,000	Focal intrarenal bleeding	–	Wilbert 1989

Table 3.8 **Injury to extrarenal organs if exposed to shock waves in experimental studies**

Organ	Animal	Observation	Author	
Liver	Rat	Hepatocellular necrosis	Loening et al Mardan et al	1988 1988
	Dog	Dose-dependent hematoma, subcapsular hematoma, and necrosis	Rassweiler et al Staritz et al Neisius et al	1989 1989 1989
Gallbladder	Dog	Hemorrhage and edema of wall	Neisius et al	1989
Lung	Rat	Petechial bleeding, hemoptysis, pulmonary interstitial cellular infiltration	Eisenberger et al Loening et al	1976 1988
	Dog	Hemorrhages, hemorrhages after gallstone destruction	Mardan et al Delius et al	1988 1987
Intestine	Rat	Petechial bleeding intestinal hemorrhages	Eisenberger et al Loening et al	1976 1988
	Dog	Submucosal hematoma, intestinal hemorrhage	Rassweiler et al Jäger et al	1989 1989
Ureter	Rabbit	No damage	Fuchs et al	1989
Adrenals	Dog	No adverse effect on function or morphology	Chinn et al	1988
Ovary and fetus	Rat	No adverse teratogenic effect	McCullough et al	1988
Bone	Rabbit	Aseptic necrosis damage to osteocytes	Graff et al	1987
	Rat	Dose-dependent hemorrhagic lesion	Mardan et al	1988

Table 3.9 **Effects of shock waves (SW) on cells in culture**

Cells	Results	References	
Full blood	In vitro: dose-dependent hemolysis In vivo: no increase in free plasma Hemoglobin in peripheral blood in dogs	Eisenberger et al	1977
Human lymphocytes	Proliferation unaffected	Eisenberger et al	1977
Human neutrophils	In suspension: cellular disruptions, swelling of mitochondria, plasma-membrane ruptures; permeability and cytoskeletal changes	Holmes et al	1988
Human melanoma	Reduction in cell viability, decrease in colony formation, selective diminution of cells in G2 and M phases.	Russo et al	1987
	No influence on cell cycle, 10-fold potentiated growth inhibition when treated at 18°C compared to 37°C and 42°C	Berens et al	1988
Human renal carcinoma, normal human embryonic kidney	Dose-dependent reduction of viability, in vitro lysis, total inhibition of multiplication for 5 days after 2,000 SW	Chaussy et al	1989
Human cervix carcinoma	No influence of cell cycle, 10-fold potentiated growth inhibition when treated at 18°C compared to 37°C and 42°C.	Berens et al	1988
	In suspension: dose-dependent damage; immobilized cells: no effect	Bräuner et al	1989
Rat prostatic carcinoma	Reduction in cell viability, decrease in colony formation, selective diminution of cells in G2 and M phases, delay in tumor growth after reimplantation. Mitochondria swollen, distorted cristae, in vivo exposure had no distinct histopathologic or ultrastructural effect.	Russo et al	1986
	In suspension: growth delay, ultrastructural damages; in vivo: growth delay	Loening et al	1988
	Dose-dependent inhibition of cell viability and colony growth; Cells pretreated with SW became more sensitive to chemotherapy or immunotherapy	Oosterhof et al	1988
	6 day prolonged tumor growth after SW plus cisplatin	McCullough et al	1989
Mouse bladder tumor	Palpable tumors were not affected by 800 or 1,400 SW; 2,000 SW lead to a significant inhibition of growth	Chaussy et al	1989
Mouse leukemia	In suspension: dose-dependent damage, immobilized cells: no effect	Brümmer et al	1989
Mouse mammary tumor	In suspension: dose-dependent damage, immobilized cells: no effect	Bräuner et al	1988

However, later experiments found significant damage of human neutrophils.

- Several studies using suspensions of different tumor cells showed dose-dependent cellular injury resulting in decrease of viability and colony formation (Fig. 3.**31**).

However, later experiments proved that tumor cells, if immobilized in gelatine, were unaffected (Fig. 3.**31**). The same applied to tumor cell spheroids (Figs. 3.**32**, 3.**33**).

The explanation for these different observations may be that the cellular damage in vitro

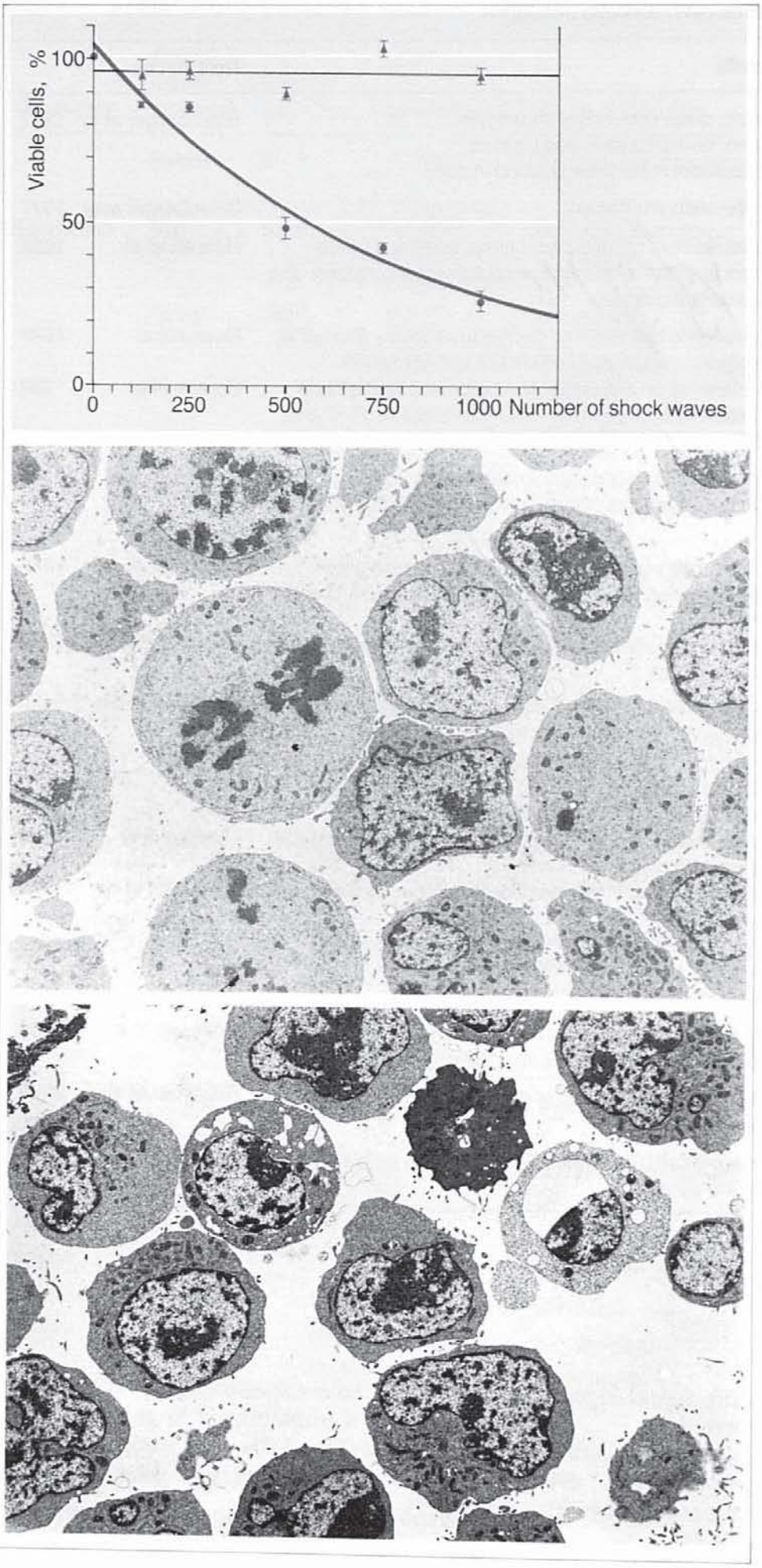

Fig. 3.31 **Effect of shock waves on viability of L1210 mouse leukemia cells**

a Schematic drawing of viability
Lower curve: single cell suspension (18 kV, 80 nF, 1 Hz, 21 °C).
Upper curve: In gelatine immobilized cells (18 kV, 80 nF, 1 Hz, 21 °C).

b Electron-microscopic picture. Control

c Electron-microscopic picture. 500 shock waves (18 kV, 80 nF, 1 Hz, 37 °C). Note fragmented cells, swollen mitochondria, perinuclear cisternae, and vacuolization of cytoplasma.

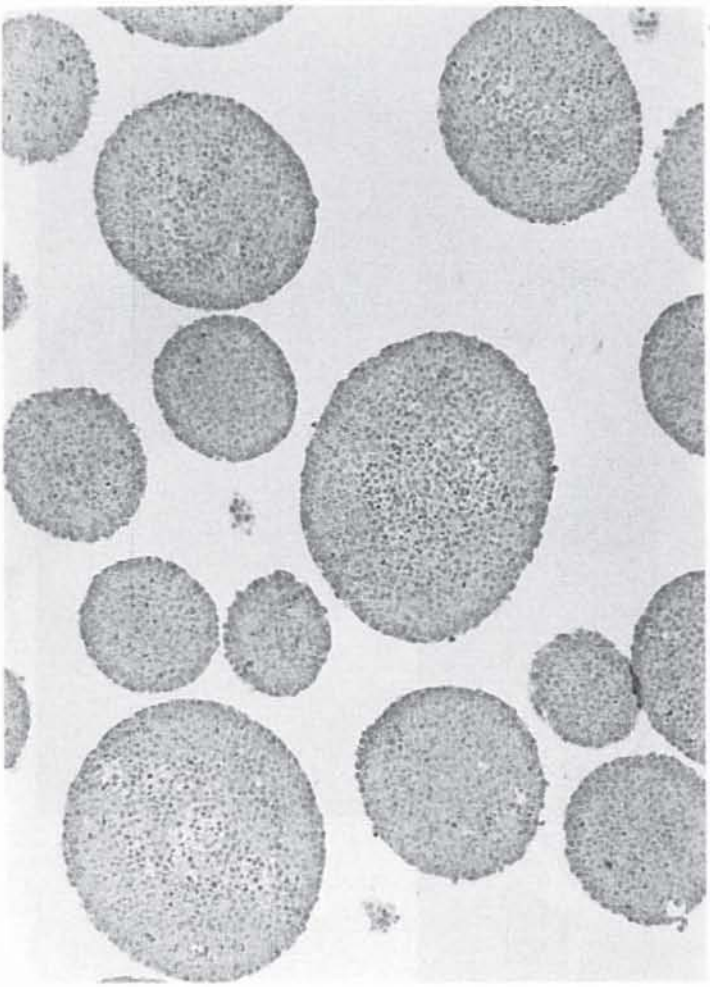

a

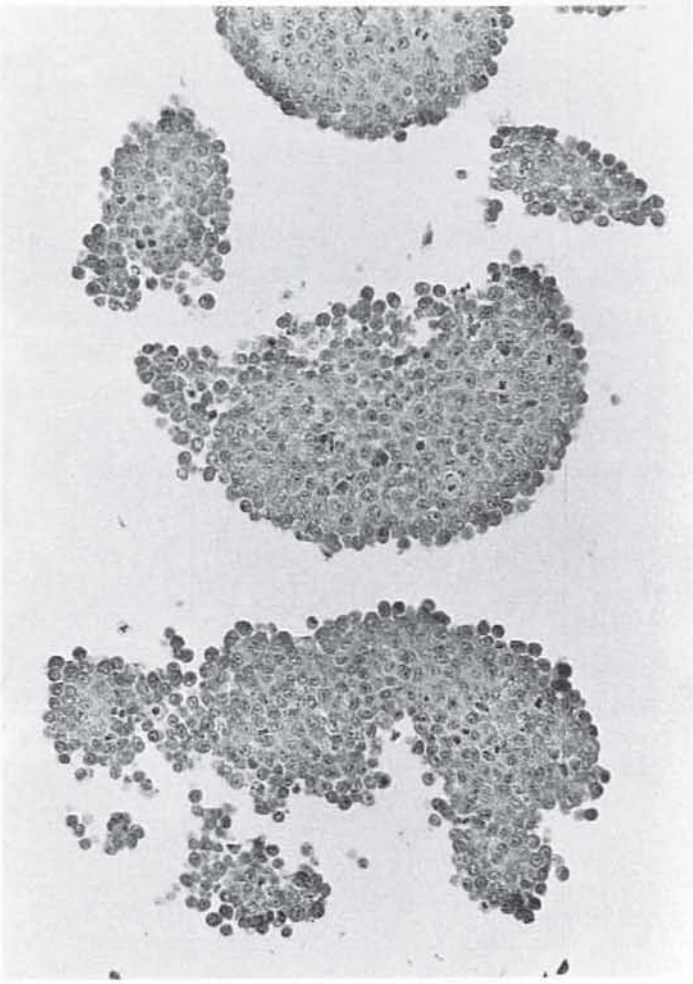

b

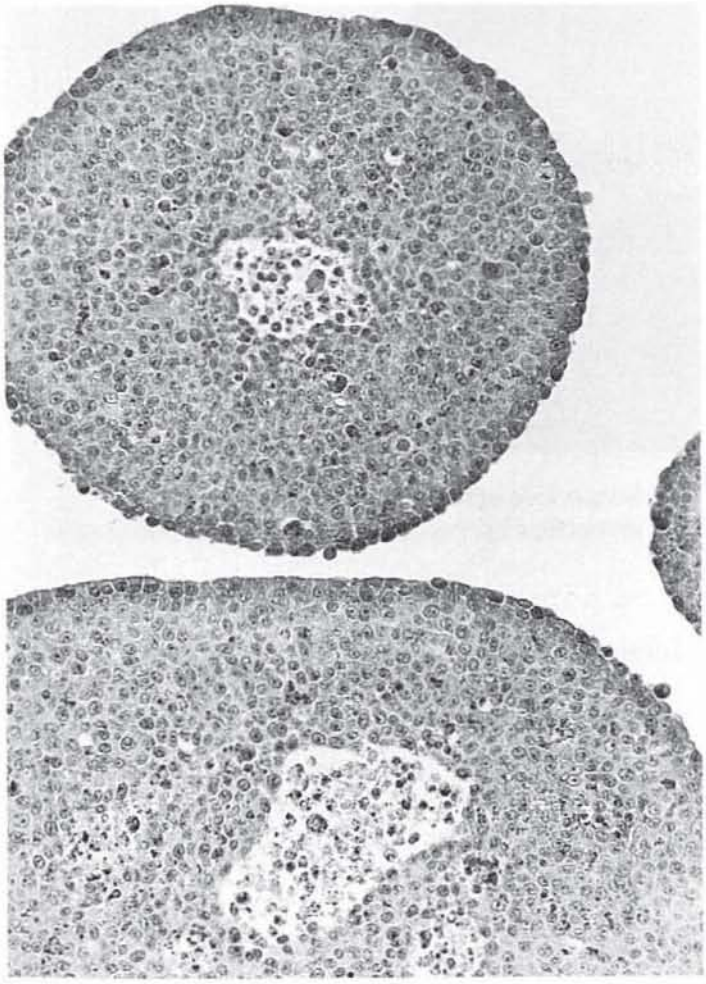

c



d

Fig. 3.32 **Light microscopic histology of multicell spheroids** (human cervix carcinoma HeLa)

a Untreated controls

b 500 shock waves (18 kV, 80 nF, 1 Hz)

c 500 shock waves (18 kV, 80 nF, 1 Hz) multicell spheroids embedded in 12% gelatine

d Gelatine blocks at the focus of an eletromagnetic shock wave generator. Note the absence of cavitation bubbles

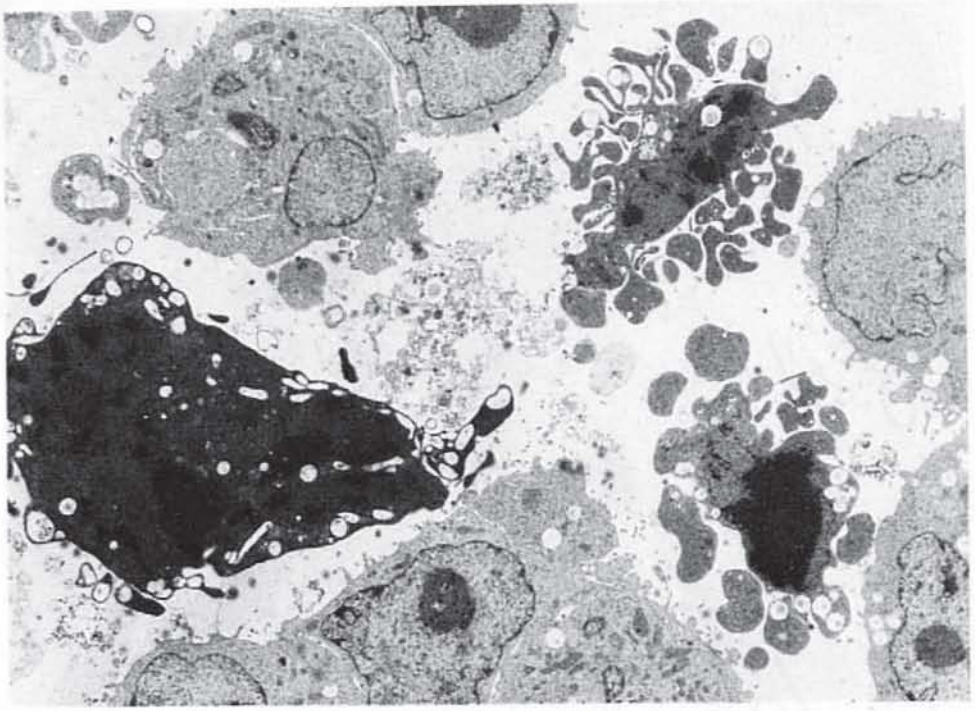

a

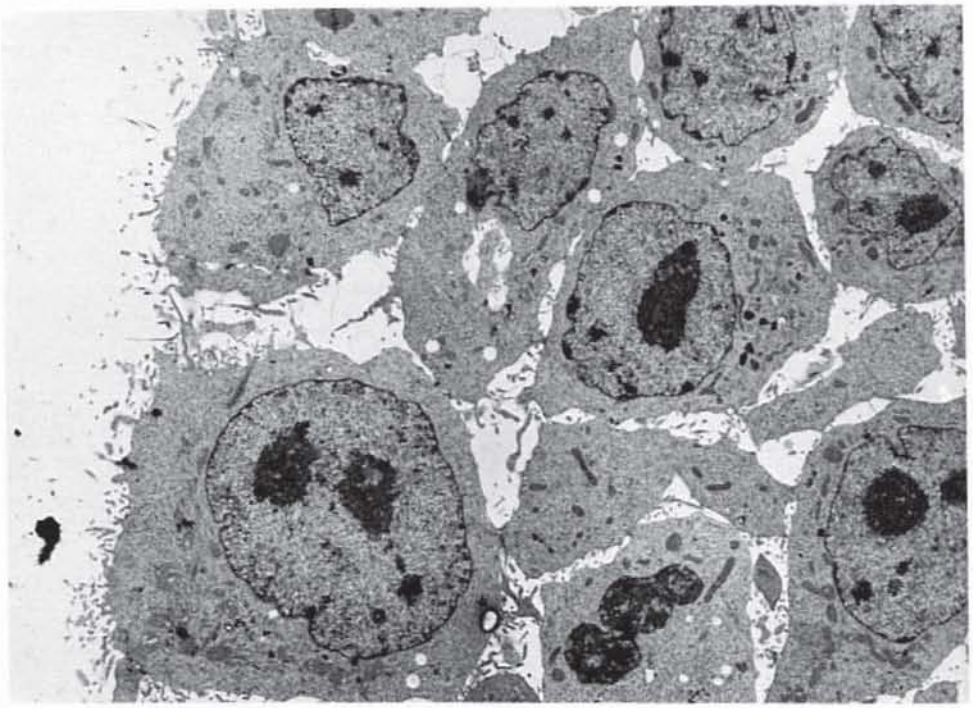

b

Fig. 3.33 **Electron-microscopic histology of multicell spheroids** (human cervic carcinoma HeLa)

a Suspended spheroids after 500 shocks
b Immobilized spheroids in gelatine after 500 shocks

depends on different mechanisms than the injury of tissue in vivo.

Whereas the peak pressure of the shock wave *in vivo* represents the main factor, *in vitro* (in suspension) secondary effects, due to cavitation and shock wave induced jets, participate in cellular destructions (Fig. 3.**34**). These rapid accelerations of the cells expose them to stress forces and cause collisions.

Immobilization of the cells in gelatine avoids these secondary effects (Fig. 3.**32d**), and thus cellular damage only occurs if very high levels of peak pressure are applied. This observation correlates with the significant attenuation of shock wave efficacy treating impacted ureteral calculi.

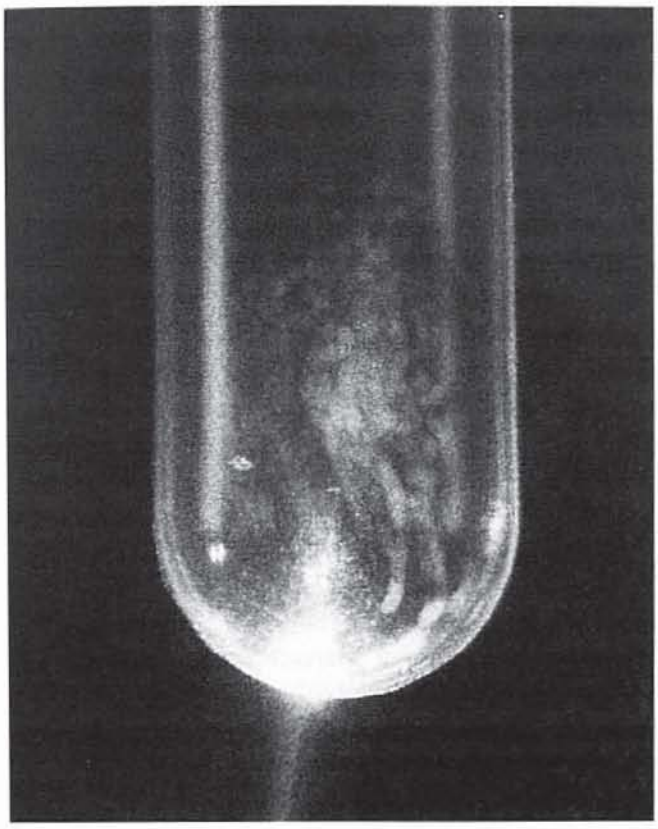

All in vivo experimental tumor models showed some growth delay after shock wave application; however, complete tumor necrosis could not be achieved. Preliminary studies found an increase of chemosensitivity of the tumor when pretreated by shock waves (Fig. 3.**35**). Recently, even a synergistic antineoplastic effect of shockwaves and biological response modifies was observed experimentically (Oosterhof et al. (1990). Nevertheless, all these trials are still a long way from clinical application.

Fig. 3.**34** **HeLa multicell spheroids in a polyethylene pipette** (diameter: 1.3 cm) exposed to a single shock wave (18 kV, 80 nF, 37 °C). Stroboscopic illumination

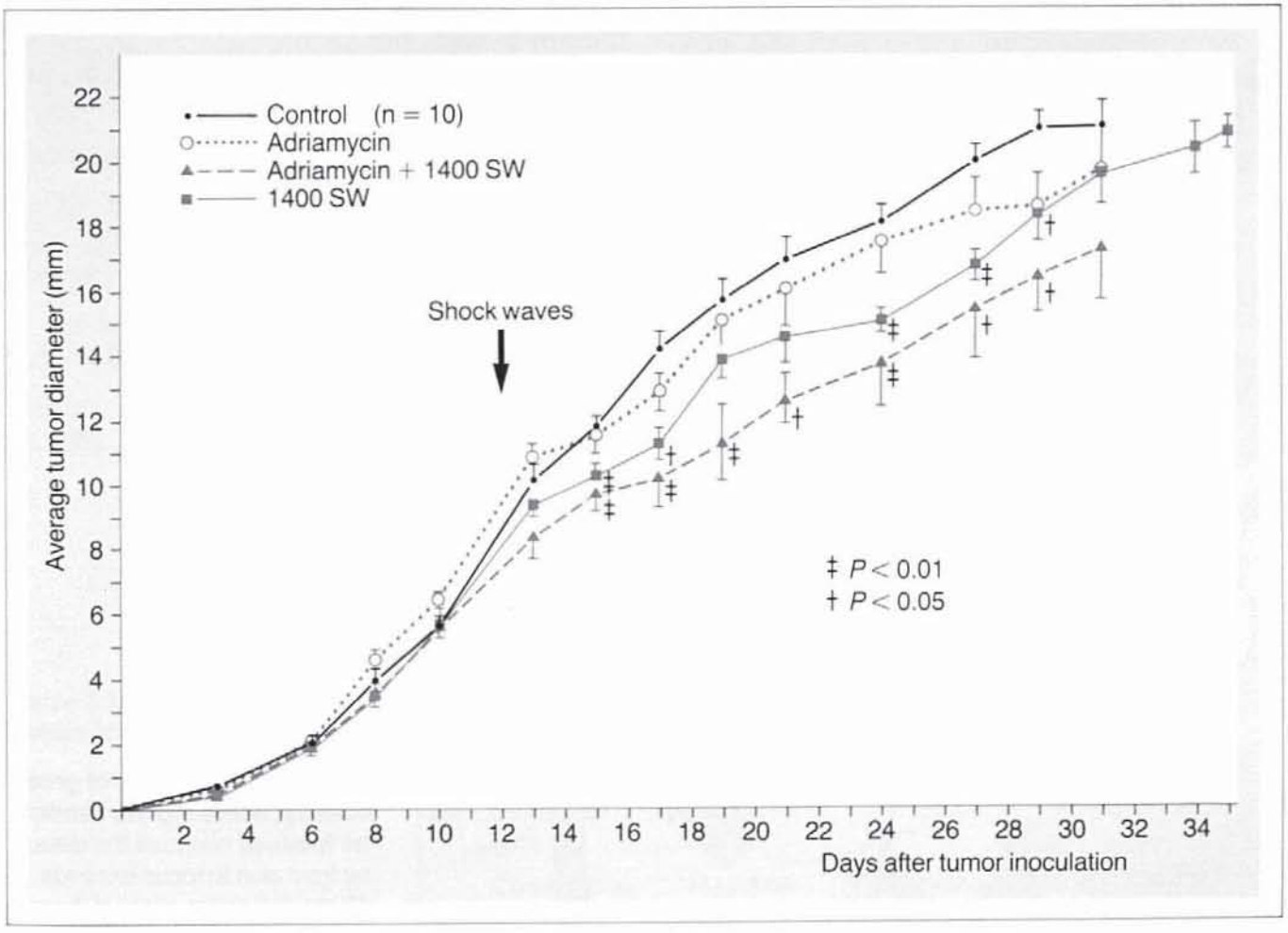

Fig. 3.**35** **Synergistic effect of shock waves and chemotherapy in the bladder tumor model (FANFT) of C_3H/HE mice** (from Chaussy and Fuchs, 1989)